

PATIENT

Bunkie Parrott

SPECIES

Canine

BREED

Havanese Mix

SEX

MN

AGE

12yr

WEIGHT

9.8kg

INTERPRETED BY

Eric Lindquist, DMV
DABVP, Cert. IVUSS

IMAGING PERFORMED BY

Dr. Hayley
Biederbeck

HOSPITAL NAME

Lomsnes Veterinary
Hospital

REFERRING VET

Dr. Hayley
Biederbeck

INVOICE

24160

DATE

03/10/2026

PRESENTING CLINICAL SIGNS

- Chronic Cushing's. Elevated AlkP chronically, ALT elevation is new.
- Otherwise clinically normal aside from tntc cysts/warts. Anes today to remove some of these that were bothering him and u/s liver at end of sx.
- Chronic recurrent urolithiasis
- Prev sent u/s to sonopath but has been a while
- Abnormal PE/Chem/CBC/UA Results: AlkP 1885, was 1951 Sept/2025. ALT - 187, has not been elevated previously GGT/Tbili normal as well as remainder of cbc/chem USG 1.030.

LIMITED ULTRASONOGRAPHIC EXAMINATION OF THE ABDOMEN

Liver

The liver was uniformly swollen with minor coalesced gallbladder debris and over distension with dependent and suspended bile without evidence of overt mucocele formation. However, excessive sludge was present. The liver presented coarse architecture with mildly increased portal markings and subtle, mixed echogenic changes. This is consistent with vacuolar hepatopathy and some level of remodeling and history of inflammatory component. Multifocal hypoechoic non-disruptive nodular changes noted in the liver with occasional parenchymal cysts.

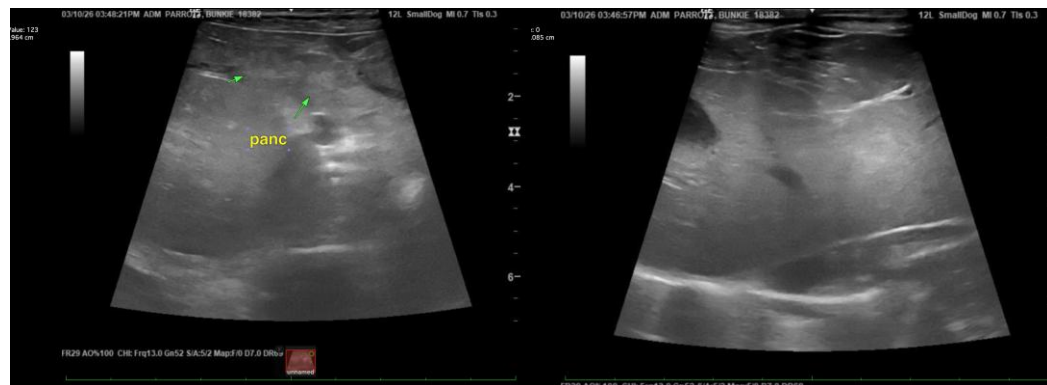
The visible pancreas is unremarkable with mild pancreatic remodeling.

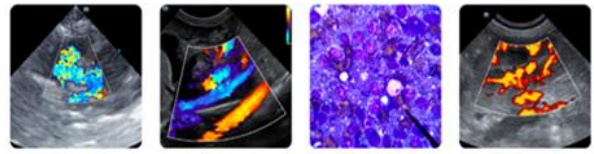
ULTRASONOGRAPHIC FINDINGS

- Subjectively benign vacuolar hepatopathy nodular hyperplasia pattern
- Pancreatic remodeling-subjectively benign

INTERPRETATION OF THE FINDINGS & FURTHER RECOMMENDATIONS

Liver FNA could be considered for further definition. Underlying endocrinopathy may be an issue in this patient. Further imaging of the adrenal glands and assessment of UA and Cushingoid signs is recommended.





PATIENT

Bunkie Parrott

SPECIES

Canine

BREED

Havanese Mix

SEX

MN

AGE

12yr

WEIGHT

9.8kg

INTERPRETED BY

Eric Lindquist, DMV
DABVP, Cert. IVUSS

IMAGING PERFORMED BY

Dr. Hayley
Biederbeck

HOSPITAL NAME

Lomsnes Veterinary
Hospital

REFERRING VET

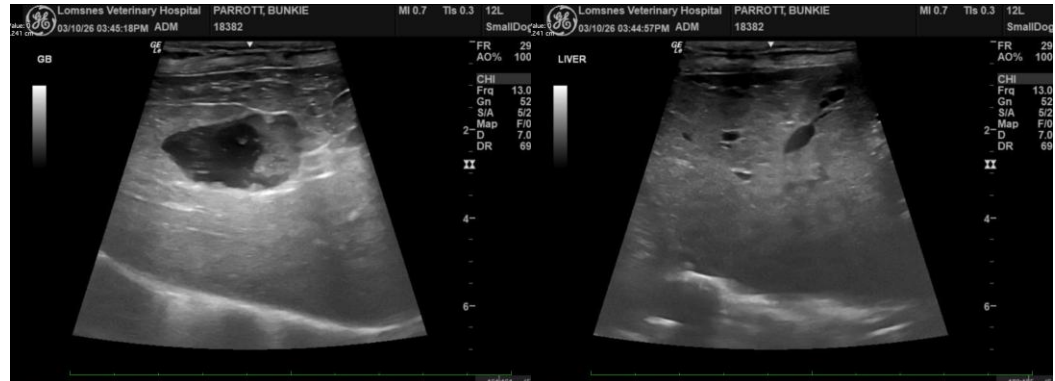
Dr. Hayley
Biederbeck

INVOICE

24160

DATE

03/10/2026



The information and recommendations provided are based on the images presented by the referring veterinarian/sonographer. No evaluation can be communicated regarding pathology that was not visible in the image/video clips provided.

Thank you for this referral. If the clinical or image interpretation does not parallel your findings or if I can be of any further assistance, please contact me.

Eric Lindquist, DMV, DABVP(CFM), Cert. IVUSS,
CEO, Owner, Founder -- SonoPath.com
info@SonoPath.com